

## Pancarpal arthrodesis in the dog

Professor John Innes BVSc PhD CertVR DSAS(orth) MRCVS  
RCVS Specialist in small animal surgery (orthopaedics)



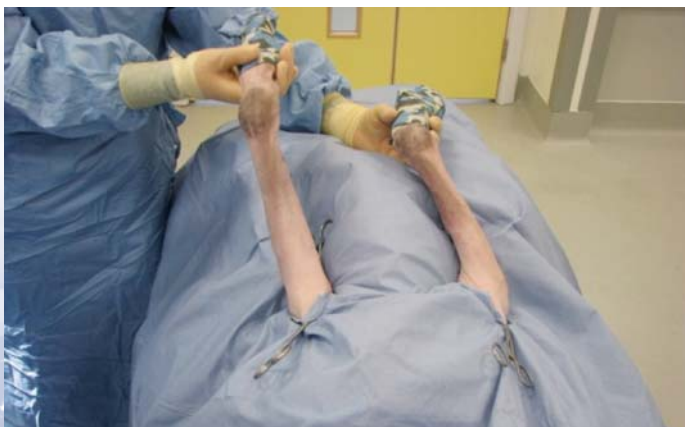**VETERINARY  
TISSUE BANK**

### Indications

- 1 Palmar ligament rupture (traumatic and degenerative)
- 2 For radiocarpal bone fractures in breeds such as Boxers (Li and others 2000)
- 3 End-stage carpal arthritis (osteoarthritis, infective arthritis or erosive immune-mediated arthritis)  
For non-reconstructable carpal fractures
- 4 As part of limb salvage for osteosarcoma of the distal radius and ulna

### Patient preparation

The limb is clipped from just below the elbow joint to the level of the main carpal pad. An impervious barrier is taped in position over the toes. The patient is positioned in dorsal recumbency with the operative limb retracted caudally. Bilateral surgeries under the same anaesthetic are possible if required. The limb is free-draped and a sterile impervious drape wrapped over the foot. Sterilised cohesive dressing can then be tightly wrapped around the foot and progressed proximally to act as an Esmarch bandage; at the level of the proximal antebrachium, the dressing can be twisted in to a rope and used as a tourniquet.

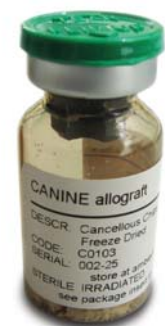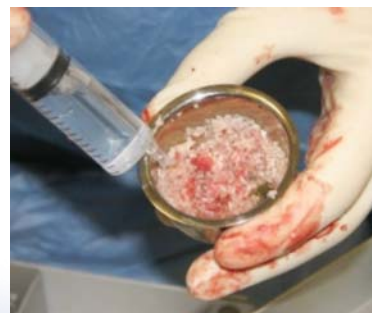


### Surgical approach

A skin incision is made through the cohesive dressing on the dorsal aspect of the carpus from the distal third of the antebrachium to the distal third of the third metacarpal bone. Care is taken to avoid the cephalic vein. The subcuticular tissues can then be stapled or sutured to the cohesive dressing on each side of the incision to isolate the wound.

Subcutaneous tissues are incised and the extensor carpi radialis tendon of insertion is identified on the medial aspect of the carpus. Lateral to this is the common tendon of the digital extensor muscle and this must be protected. Fascia between the ECR tendon and the CDE tendon is incised and the CDE tendon retracted laterally.

The joint capsule at all three joint levels is incised and the carpus flexed to open the joint space. Articular cartilage is removed using a combination of sharp dissection and curettage with manual or powered instruments. The subchondral plate of the radius is penetrated with 2-3 small drill holes to encourage mesenchymal cell migration.



### Bone graft preparation

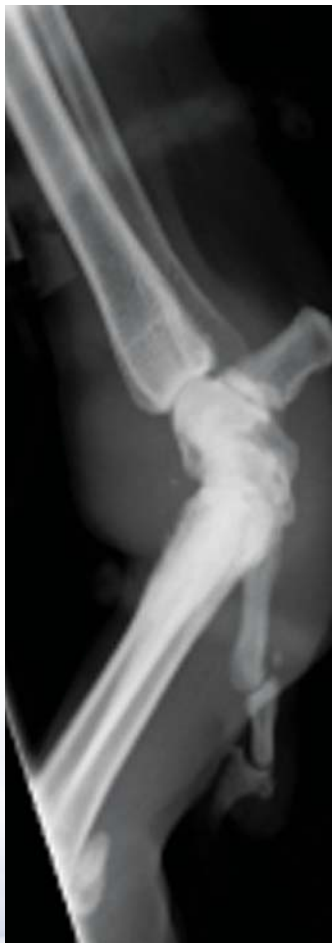A suitable vial of Veterinary Tissue Bank freeze-dried canine cancellous chips with a vial is chosen and rehydrated with sterile Hartmann's solution in a Galli pot. Graft volume is approximately 1cc for small dogs, 3cc for medium-sized dogs and 5cc for large/giant breeds.

Demineralized bone matrix (DBM) (Hoffer and others 2008) as available from Veterinary Tissue Bank may be mixed with the allograft chips to further enhance osteoinduction.

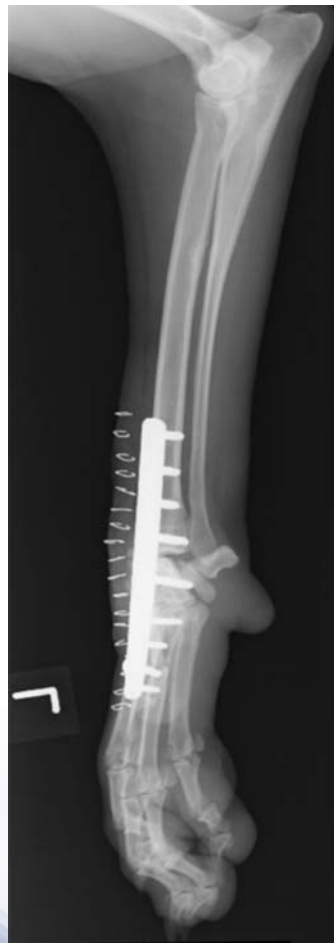## Implant placement

A suitable plate is positioned such that a central screw hole is positioned over the radial carpal bone. The screw is placed and then the most proximal and distal screw holes are filled with appropriate screws such that the surgeon is happy with the implant placement. The screws and plate are carefully removed and the Veterinary Tissue bank allograft and DBM is packed in to all the joint spaces. The plate is replaced and the screws re-inserted before inserting all remaining screws in a routine fashion.

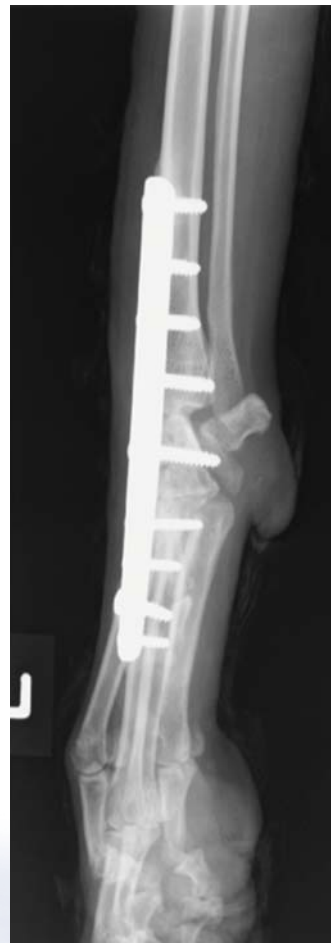## Case example – 2yo crossbred dog with bilateral carpal hyperextension



A



B



C

A, Right carpal hyperextension. B, Left carpus post-operatively. C, Left carpus at 10 weeks; fused in the expected timeframe using Veterinary Tissue Bank allograft

## References

Hoffer, M. J., Griffon, D. J., Schaeffer, D. J., Johnson, A. L. & Thomas, M. W. (2008) Clinical applications of demineralized bone matrix: A retrospective and case-matched study of seventy-five dogs. *Veterinary Surgery* 37, 639-647

Li, A., Bennett, D., Gibbs, C., Carmichael, S., Gibson, N., Owen, M., Butterworth, S. J. & Denny, H. R. (2000) Radial carpal bone fractures in 15 dogs. *Journal of Small Animal Practice* 41, 74-79.

