

## Treatment of diaphyseal fractures in dogs

John Innes BVSc PhD CertVR DSAS(orth) MRCVS  
Small Animal Teaching Hospital,  
University of Liverpool, UK



VETERINARY  
TISSUE BANK

### Introduction

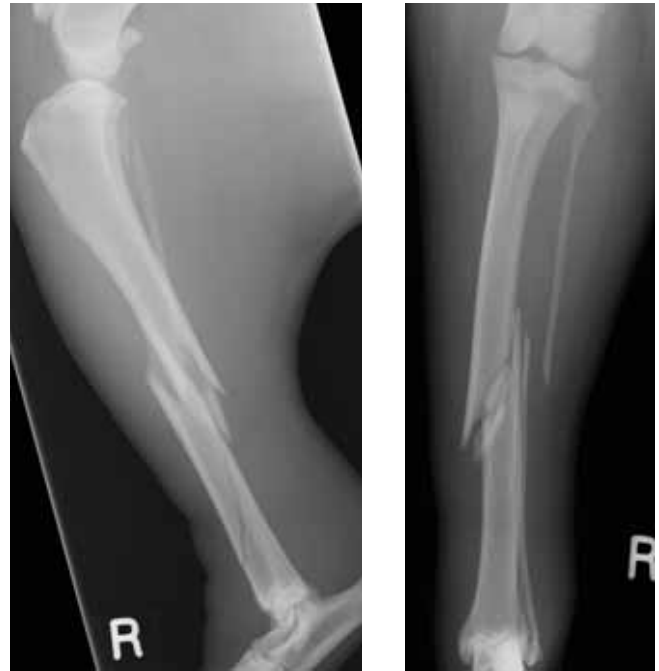Diaphyseal fractures in dogs can be challenging, particularly if the fracture is comminuted. Various fracture fixation methods are available including plate and screw fixation, interlocking nail, external skeletal fixation and intramedullary pin with cerclage wire. However, there is general agreement that bone grafting of diaphyseal fractures in skeletally mature patients results in improved bone healing. Bone grafting is strongly advised if:

- If the patient is skeletally mature
- The fracture is comminuted
- Blood supply is poor (e.g. distal tibial and radial fractures)
- Patient factors suggest slow bone healing (e.g. aged animal, toy breed, comorbidity, other injuries)

Demineralised bone matrix (DBM) (Veterinary Tissue Bank) provides a convenient method to promote bone healing through osteoinduction (Hoffer and others 2008).

### Case example: comminuted diaphyseal tibial fracture in a 5 year old 29kg crossbred dog

This dog was involved in a road traffic accident and sustained a closed, comminuted fracture of the right tibial diaphysis with severe bruising of the soft tissues. There were no other significant injuries. The fracture was considered “reconstructable” (Figure 1) and neutralisation plate and screw fixation was planned. As is policy for all diaphyseal fractures in skeletally mature dogs, bone grafting of the fracture site was also planned.



**Figure 1: Mediolateral and craniocaudal radiographs of the comminuted, mid-diaphyseal fracture; use of DBM was planned to optimize bone healing.**

### Patient preparation

The dog was stabilised overnight following the trauma and was prepared for surgery the following day. Following induction of anaesthesia, an epidural anaesthetic was administered using a combination of morphine and bupivacaine. The right pelvic limb was clipped and prepared from the level of the proximal femur to the main pad of the pes. The dog was placed in right lateral recumbency for surgery via a medial approach to the right tibia.

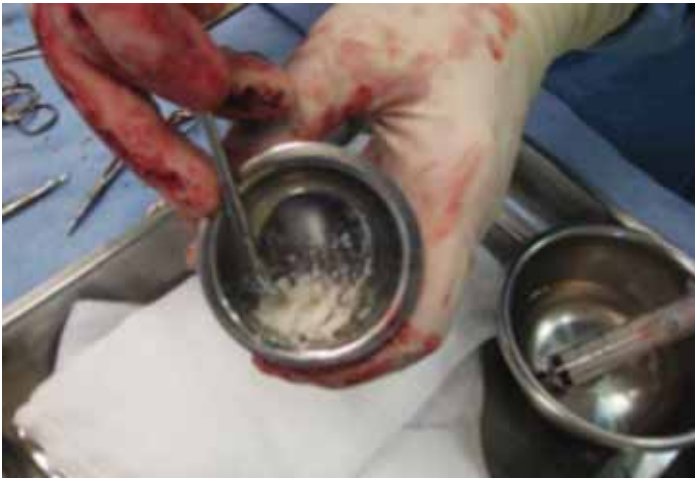### Surgical approach

A craniomedial incision over the tibia was made and the underlying fascia incised. The saphenous vein was preserved. A combination of lag screws and cerclage wire were used to reconstruct the distal fragment. A 14-hole broad 3.5 DCP was contoured to the craniomedial aspect of the tibia and applied to the bone to fixate the proximal and distal fragments.

*Continued...*

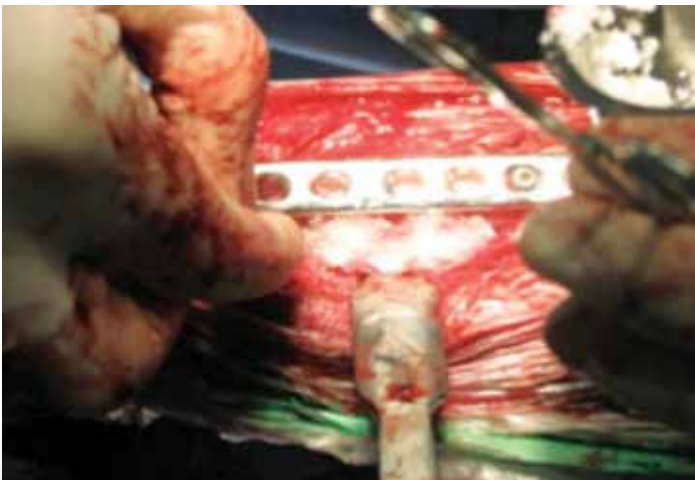
## Bone grafting

A 3cc vial of Veterinary Tissue Bank Demineralised Bone Matrix (DBM) was opened and rehydrated (Figure 2).



**Figure 2: The DBM is rehydrated 10 minutes prior to intended use**

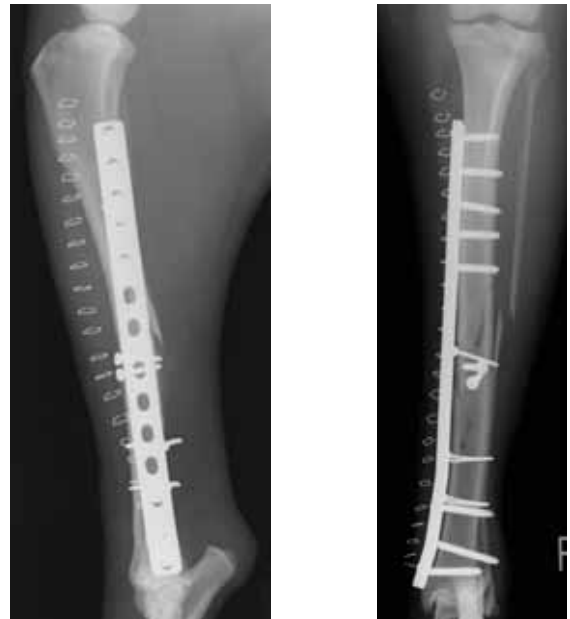The graft was packed around the fracture site (Figure 3) prior to routine closure.



**Figure 3: The rehydrated DBM was packed around the reconstructed fracture**

## Post-operative care

Radiography revealed good fracture reduction and reconstruction with satisfactory placement of all implants (Figure 4). The dog was discharged with analgesics for the next 8 weeks. Initially this involved a combination of carprofen (Rimadyl, Pfizer) and paracetamol/codeine (Pardale V) for five days, with continued analgesia on carprofen only.



**Figure 4: Immediate post-operative radiographs**

## Follow-up

Fracture healing progressed and at 8 weeks, this severe comminuted fracture exhibited radiographic union. The dog was walking without lameness and clinical progress was uneventful with return to full function at 4 months post-operatively.

## Further reading

Hoffer, M. J., D. J. Griffon, D. J. Schaeffer, et al. (2008). "Clinical applications of demineralized bone matrix: A retrospective and case-matched study of seventy-five dogs." *Veterinary Surgery* 37(7): 639-647.

