

# Use of canine cancellous chips allograft and demineralised bone matrix (DBM) for delayed fracture union and fracture non-union

Professor John Innes BVSc PhD CertVR DSAS(orth) MRCVS  
RCVS Specialist in small animal surgery (orthopaedics)



VETERINARY  
TISSUE BANK

## Indications

- 1 Atrophic non-unions of the radius and ulna  
**Key point!** These often occur in small and toy breed dogs. These patients present a particular challenge because there is often insufficient autogenous bone graft available and there is considerable risk of complications associated with harvest of bone graft.
- 2 Hypertrophic non-unions (e.g. unstable mid-shaft femoral non-unions)
- 3 Tibial delayed and non-unions

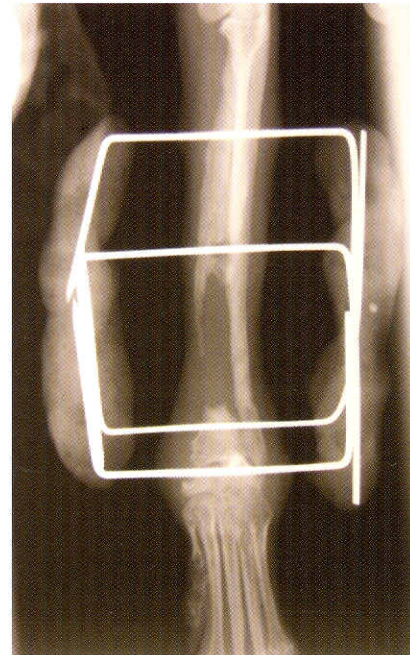
## Contraindications

- 1 Osteomyelitis

## Surgical planning

Careful consideration should be given to the underlying reasons for delayed or non-union. This may relate to patient breed or age, co-morbidity, infection, or instability. Combinations of these factors can occur.

The surgeon should think particularly about providing a stable mechanical environment, preserving blood supply and providing a biological stimulus to the fracture site. Often the most appropriate fixation method will be plate and screw fixation, with compression if appropriate and possible.



## Case example – 11 month old Chihuahua

**Figure 1: This atrophic non-union is in a 1.9kg Chihuahua which had been initially treated with external skeletal fixation (photo courtesy Carlos Macias, Centro Veterinario de Referencia Bahia de Malaga, Spain). There is a significant bone defect and autogenous cancellous graft will be in inadequate supply in a very small patient such as this.**

**Key point!** A combination of allograft and DBM provides species-specific osteoconductive and osteoinductive properties to optimise fracture healing.

## Patient preparation

The operative site is clipped and prepped as for normal elective surgery. If autogenous cancellous graft is also to be used, the donor area is clipped and prepped; allograft and DBM may be used as a graft extender.

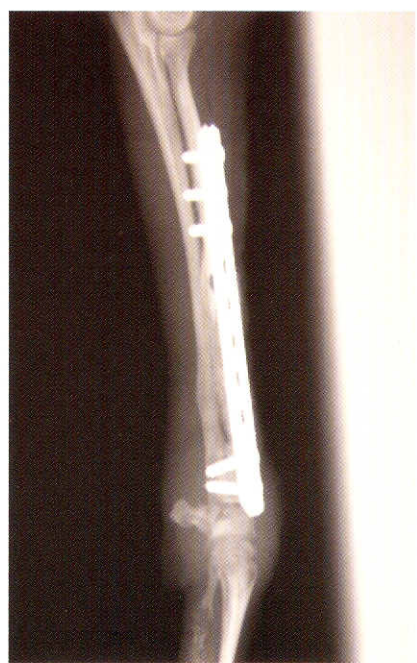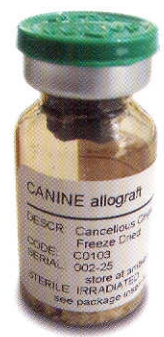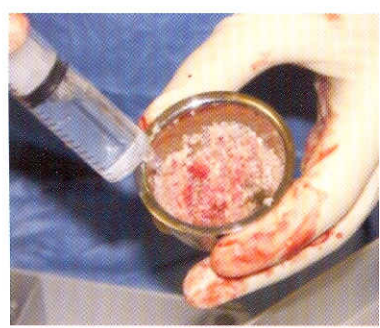## Surgical approach

The fracture is approached using a standard approach. The surgeon should preserve viable soft tissues. Non-viable tissue (e.g. sequestrate) should be removed.

*Continued...*

## Bone graft preparation

A suitable vial of Veterinary Tissue Bank freeze-dried canine cancellous chips with a vial is chosen and rehydrated with sterile Hartmann's solution in a Galli pot. Graft volume is matched to the size of the defect present. Approximately 3cc for small dogs, 5cc for medium-sized dogs and 10cc for large/giant breeds.



Case example – 11 month old Chihuahua

**Figure 2: Post-operative radiograph: Mini-plate fixation in conjunction with canine cancellous chips allograft (1-2mm chips) (Veterinary Tissue Bank Ltd). (Photo courtesy Carlos Macias, Centro Veterinario de Referencia Bahia de Malaga, Spain)**

Demineralized bone matrix (DBM) (Hoffer and others 2008) as available from Veterinary Tissue Bank is mixed with the allograft chips to further enhance osteoinduction.

## Implant placement

For fractures such as this, internal fixation with plate and screw fixation provides the most stable environment for bone formation. The specific challenge in this case is to achieve sufficient bone purchase in the distal fragment. Because bone stock distally is limited, the biological environment needs to be optimised with bone graft to facilitate bone formation in as short a time span as possible. One could consider use of an allograft cortical strut to provide mechanical support.

## References

Hoffer, M. J., Griffon, D. J., Schaeffer, D. J., Johnson, A. L. & Thomas, M. W. (2008) Clinical applications of demineralized bone matrix: A retrospective and case-matched study of seventy-five dogs. *Veterinary Surgery* 37, 639-647.



**Veterinary Tissue Bank Ltd**  
Unit 3, The Long Barn  
Brynkinalt Business Centre  
Chirk, Wrexham, LL14 5NS, UK  
Tel: +44 (0)1691 778769  
Fax: +44 (0)5603 411520  
[www.vtbank.org](http://www.vtbank.org)